## Intraosseous cannula placement site by patient age

| Patient age | Intraosseous site |
|---|---|
| Infant (under 1 year) | Proximal tibia |
| | Distal femur |
| Child (1-12 years) | Proximal tibia* |
| | Distal tibia or fibula |
| Skeletally immature adolescent• (12-18 years) | Proximal tibia* |
| | Distal tibia or fibula |
| | Sternum[Δ] |
| Over 18 years | Proximal tibia* |
| | Proximal humerus[◇] |
| | Distal tibia or fibula |
| | Sternum[Δ] |

* Battery-powered or impact-driven devices are typically required to place an intraosseous cannula through the bony cortex of the proximal tibia in patients older than six years of age.
• Age at full skeletal maturity varies according to gender and individual patient characteristics.
Δ Sternal intraosseous cannula placement should only be attempted using devices specifically designed for that placement site.
◇ The proximal humerus site should only be used in skeletally mature patients.

UpToDate®

Copyrights apply

## Venous drainage from marrow of long bone with intramedullary needle in place

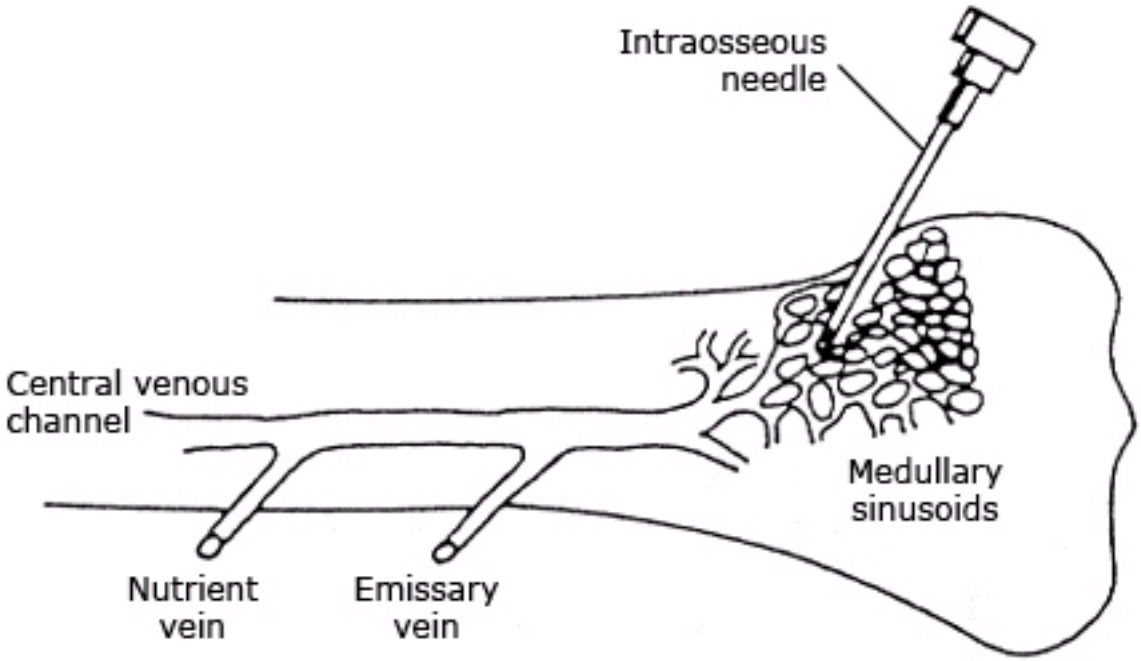


The veins that drain the medullary sinuses of the long bones are supported by the bony matrix. They do not collapse in shock or hypovolemia.

*Reproduced with permission from: Barkin RM (Ed). Pediatric emergency medicine: Concepts and clinical practice, 2nd ed, Mosby, St. Louis, 1997. p.151. Copyright © 1997 Mosby.*

UpToDate®

Copyrights apply

## Proximal tibial intraosseous access site

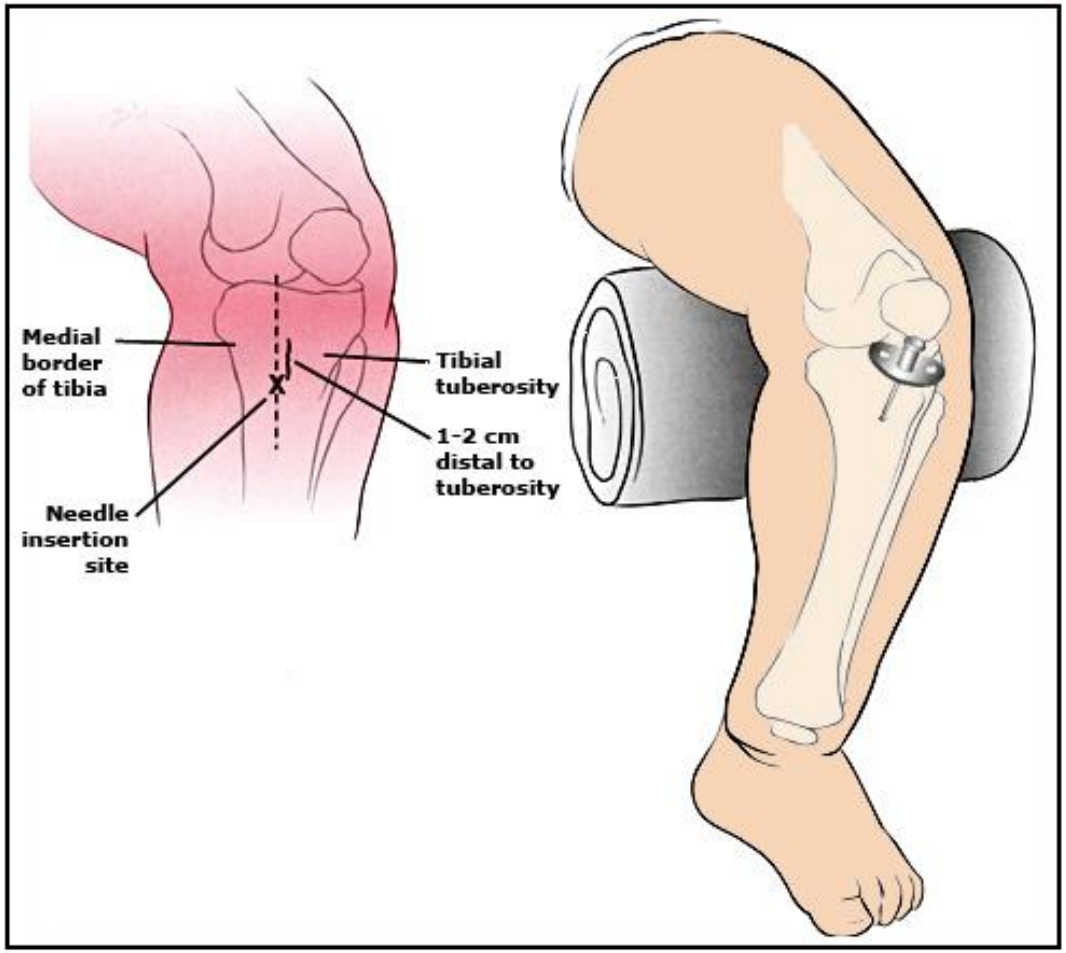


Entry site at the proximal tibia.

*Reproduced with permission from: Hodge Dee III. Intraosseous infusion. In: Textbook of Pediatric Emergency Procedures, 2nd ed, King C, Henretig FM (Eds), Lippincott Williams & Wilkins, Philadelphia 2008. Copyright © 2008 Lippincott Williams & Wilkins. www.lww.com.*

UpToDate®

Copyrights apply

## Intraosseous cannulation technique

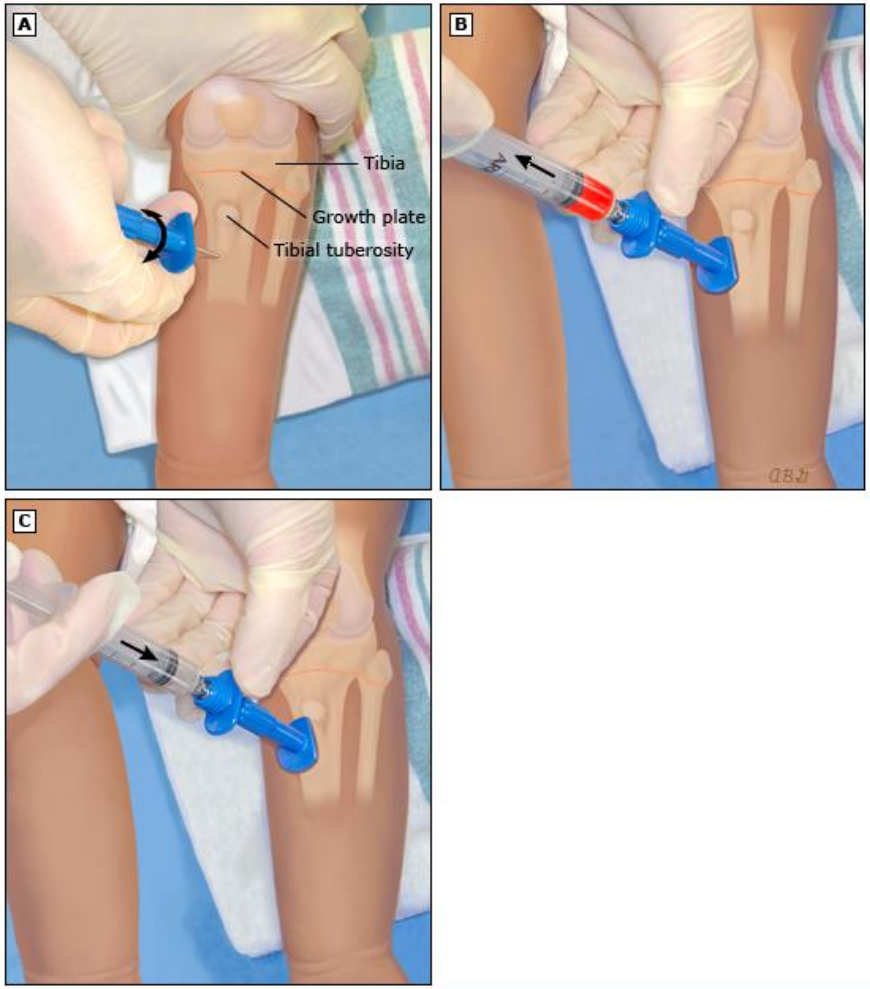


(A) Insert the needle in the proximal tibia on the flat surface located distal and medial to the tibial tuberosity. Direct the needle caudad (away from growth plate) at a 10 to 15 degree angle. Use downward pressure from the heel of the hand, and a twisting motion until resistance decreases. See text for details.
(B) Marrow can sometimes be aspirated.
(C) The needle will flush easily when it is in the marrow cavity and should stand without support.
Once successful placement is established, immobilize the leg and secure the needle.

UpToDate®

Copyrights apply

## Manual intraosseous needle placement

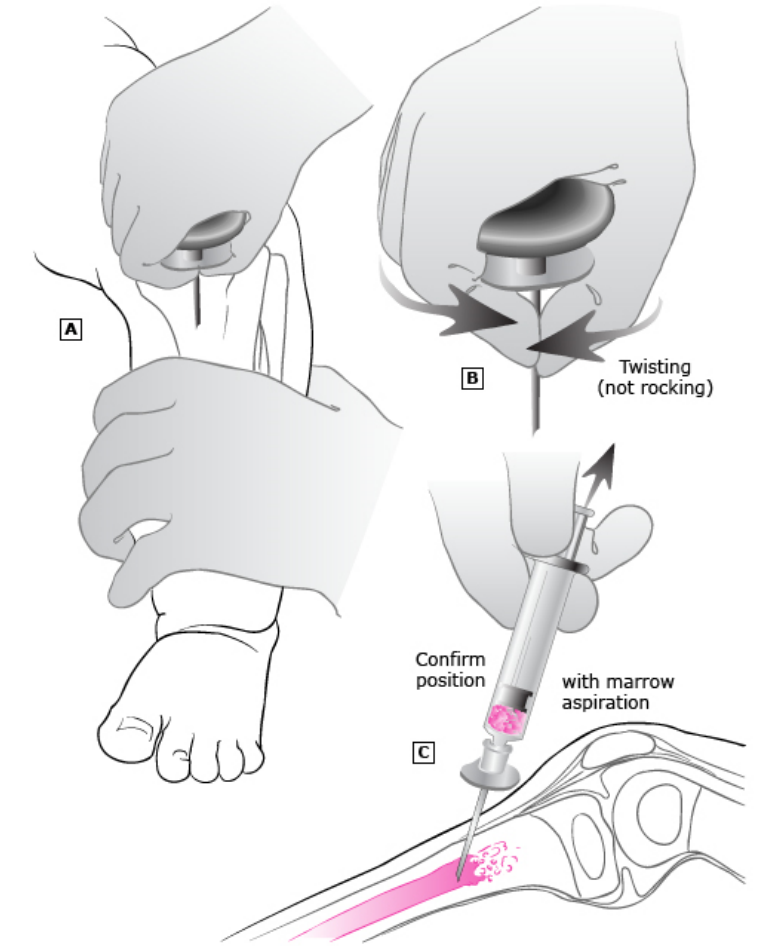


(A) The needle is angled slightly away from the joint space or, as some more recent sources have recommended, perpendicular to the bone.
(B) A back-and-forth "screwing" motion is used to insert the needle. "Rocking" the needle from side to side results in enlargement of the puncture site and extravasation of infused fluid.
(C) Intramedullary placement is confirmed by aspirating marrow.

*Reproduced with permission from: Hodge D III. Intraosseous infusion. In: Textbook of Pediatric Emergency Procedures, 2nd Edition, King C, Henretig FM, Eds. Lippincott Williams & Wilkins, 2008. Copyright © 2008 Lippincott Williams & Wilkins. www.lww.com.*

UpToDate®

Copyrights apply